

2009 Review of the 2008 OITE Exam– Powerpoint Format

Please follow instructions below – assignments listed – if younger guys have any questions – ask one of the chiefs. The younger guys should look at last years. Tips: Typically don't need any long dissertations for responses. This is just a review. If your reference is esoteric – use something like Miller Review. In order to begin the review according to the new curriculum – your information should be complete and turned in no later than February 28, 2009.

The images will be on the G drive as soon as the CD comes in from AAOS (mailed this week per aaos). Obviously, don't turn in questions without attaching the images.

1. Slide Design Template – “Stream” (Blue background with white font – should be default for this template)
2. Slide Layout – “Title and Text”: Question in title box, Answer in text box
3. Font – “Times New Roman”
4. Font size – whatever fits best on one slide
5. Change the answer bullets in the text box to numbers
6. The question should be aligned to the left, not centered
7. First slide with question and answer options
 - Next slide(s) with images(if pertinent)
 - Last slide with correct answer in title box and the explanation in the text box
8. You may comment on the reference in your answer, but do not include the reference list.

Questions due February 28, 2009

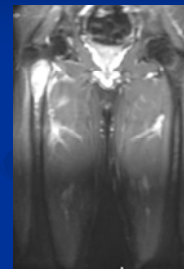
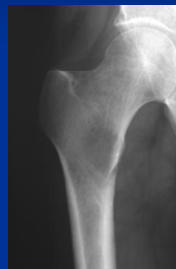
Question Assignment (13 or 14 questions each)

| | | | | |
|------------------|-----------------|-------------------|--------------------|--------------------|
| Aneja: 1-13 | Baker: 14-26 | Barr: 27-39 | Barrett: 40-51 | Booker: 52-64 |
| Curry: 65-77 | Davis: 78-90 | Fagan: 91-104 | Franz: 105-117 | Futvoye: 118-130 |
| Kellum: 131-143 | Kneip: 144-156 | Kosko: 157-169 | Maples: 170-184 | Marks: 185-196 |
| Pierce: 197-209 | Powell: 210-222 | Roberson: 223-235 | Thomasson: 236-249 | Wingerter: 250-262 |
| Woodall: 263-275 | | | | |

Questions deleted: 36, 69, 89, 130, 135 / please make a note on your slide.

84. A 57 yo man was diagnosed with localized prostate carcinoma 3 yrs ago, with negative margins and negative lymph nodes. He now reports a 3 wk h/o severe right hip pain that is worse with weight bearing. Radiographs are shown in fig 26a-b. CT scans of the chest, abdomen, and pelvis, as well as a whole body scan, are negative for other lesions. What is the next most appropriate step in treatment?

1. Right hip hemiarthroplasty
2. Locked intramedullary rod placement in the right femur
3. Biopsy of the right femur
4. Hip disarticulation
5. Curettage, cementation, and plate fixation



3. Biopsy of the right femur

Xrays and MRI show a lesion in the proximal femur of a patient with a h/o prostate cancer, but this doesn't necessarily mean this is a metastatic prostate lesion. A biopsy is indicated b/f definitive treatment is done.